

Ten-Year Multicenter Clinical and MRI Evaluation of Isolated Supraspinatus Repairs

Philippe Collin, MD, Jean-François Kempf, MD, PhD, Daniel Molé, MD, Nicolas Meyer, PhD, Charles Agout, MD, Mo Saffarini, MEng, Arnaud Godenèche, MD, and the Société Française de Chirurgie Orthopédique et Traumatologique (SoFCOT)

Investigation performed at Centre Orthopédique Santy, Lyon, France

Background: Early repair of isolated supraspinatus tears could prevent further deterioration of the rotator cuff; however, there is no consensus on the management of such tears because of a lack of long-term outcome studies. The purposes of this study were to report the 10-year outcomes of isolated supraspinatus repairs and to investigate the factors that favor healing and recovery.

Methods: We retrieved the records of all 511 patients who, in 2003, underwent repair of full-thickness isolated supraspinatus tears, performed by 15 surgeons at 15 centers. In 2014, the patients were asked to return for evaluation at a minimum follow-up of 10 years. One hundred and eighty-eight patients could not be reached, and 35 were excluded because they had a reoperation (17 had a re-rupture, 7 had conversion to an arthroplasty, and 11 had other causes). A total of 288 patients (50% were men) who had a mean age (and standard deviation) at index surgery of 56.5 ± 8.3 years (range, 32 to 77 years) were evaluated clinically, and 210 of them were also evaluated using magnetic resonance imaging (MRI).

Results: Thirty shoulders (10.4%) had complications, including stiffness (20 shoulders), infection (1 shoulder), and other complications (9 shoulders). The total Constant score improved from a mean of 51.8 ± 13.6 points (range, 19 to 87 points) preoperatively to 77.7 ± 12.1 points (range, 37 to 100 points) at 10 years. At the 10-year follow-up evaluation, the mean Subjective Shoulder Value (SSV) was 84.9 ± 14.8 (range, 20 to 100), and the mean Simple Shoulder Test (SST) was 10.1 ± 2.2 (range, 3 to 12). Of the 210 shoulders evaluated using MRI, the repair integrity was Sugaya type I in 26 shoulders (12%), type II in 85 (41%), type III in 59 (28%), type IV in 27 (13%), and type V in 13 (6%). The total Constant score at the final follow-up was significantly associated with tendon healing ($p < 0.005$) and was inversely associated with preoperative fatty infiltration ($p < 0.001$). Neither the surgical approach nor the preoperative retraction influenced the outcomes.

Conclusions: Repairs of isolated supraspinatus tears maintained considerable improvement in clinical and radiographic outcomes at 10 years. Preoperative fatty infiltration and postoperative re-rupture have a significantly detrimental effect on the long-term functional outcome of rotator cuff repair.

Level of Evidence: Therapeutic Level IV. See Instructions for Authors for a complete description of levels of evidence.

Rotator cuff tears are more common in older patients¹⁻³ and in those involved in overhead manual work and certain sports activities^{4,5}. It is estimated that 4.5 million annual patient visits in the United States concern rotator cuff tears, and nearly 250,000 of them are repaired surgically^{6,7}. Rotator cuff repair appears to substantially reduce the economic and societal burden of this pathology, potentially yielding \$3.44 billion of lifetime savings each year⁷.

While rotator cuff tears can be “silent,” or asymptomatic, it is believed that gradual degeneration causes many shoulders to become painful or symptomatic within 2 to 3 years^{5,8,9}. Most rotator cuff tears initiate within the supraspinatus tendon and could propagate to different extents and directions depending on various factors¹⁰⁻¹⁸. The progression of tendon lesions over time is important to consider in the diagnosis and treatment of both degenerative and acute rotator cuff tears¹⁹.

Disclosure: This study was financed by the Société Française de Chirurgie Orthopédique et Traumatologique (SoFCOT). On the **Disclosure of Potential Conflicts of Interest** forms, which are provided with the online version of the article, one or more of the authors checked “yes” to indicate that the author had a relevant financial relationship in the biomedical arena outside the submitted work (<http://links.lww.com/JBJS/E284>).

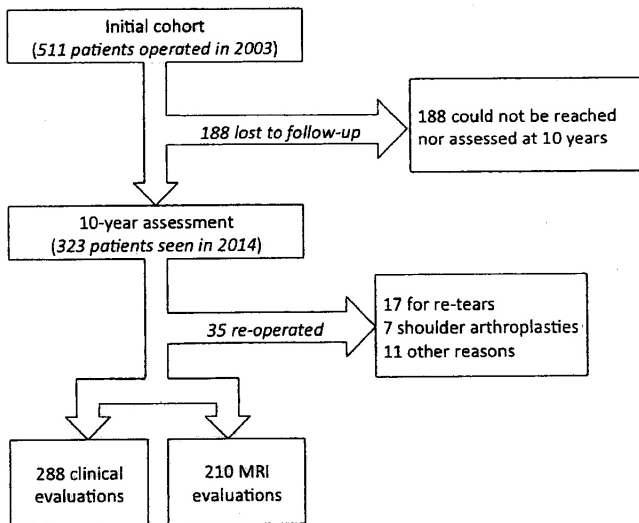


Fig. 1
Flowchart detailing inclusion and exclusion of patients from the original cohort.

Early surgical treatment of isolated supraspinatus tears may prevent further rotator cuff tendon and muscle degeneration^{8,20-22}. Numerous authors have reported considerable improvement in clinical and radiographic outcomes following repair of isolated supraspinatus tears using various surgical techniques; however, most of those studies had limitations due to small cohort sizes or a short follow-up period^{4,21,23-31}. Recent randomized controlled trials on rotator cuff tears also have demonstrated better outcomes following surgical repair compared with conservative treatment, although differences in

clinical scores were not significant and/or relevant^{32,33}. There is, therefore, little consensus on the optimal strategy to manage isolated supraspinatus tears^{24,34,35}, probably because of the lack of literature confirming that clinical and structural improvements are maintained at long-term follow-up. Moreover, most authors studied either clinical outcomes or radiographic findings, but seldom combined both aspects, which leaves doubts regarding relations between function and healing.

Therefore, the aims of the present study were to report the clinical and radiographic outcomes 10 years following repair of isolated supraspinatus tears in a sizeable cohort, and to determine factors that could favor improved healing and functional recovery. The hypotheses were that (1) improvements in clinical scores and tendon healing are maintained 10 years following surgical repair, and (2) clinical scores are associated with tendon healing.

Materials and Methods

Study Design

We retrospectively studied the records of all patients who underwent surgical repair of isolated supraspinatus tears that had been performed in 2003 by 15 surgeons at 15 centers. The inclusion criteria were adult patients with full-thickness isolated supraspinatus tears (confirmed intraoperatively) who received complete tendon repair, by either open or arthroscopic surgery. The exclusion criteria were partial-thickness tears, a history of shoulder surgery, partial tendon repairs, and concomitant lesions on other rotator cuff tendons. A total of 511 patients were identified and were asked to return in 2014 for clinical and radiographic evaluation at a minimum follow-up of 10 years. All patients provided informed consent for their participation in this study, which had been approved by the institutional review board in advance (institutional review board number 2013-A01788-37).

TABLE 1 Patient Demographics

Characteristic	Supraspinatus Tear Cohort	
	Clinical Findings Available (N = 288)	Clinical and Radiographic Findings Available (N = 210)
Age* (yr)	56.5 ± 8.3 (31.6-77.2)	56.1 ± 7.6 (31.6-77.1)
Sex (M:F)	145:143	103:107
Dominant side involved (no. [%])	209 (72.5)	153 (72.9)
Smokers (no. [%])	38 (13.2)	26 (12.4)
Previous trauma (no. [%])	78 (27.1)	54 (25.7)
Chronicity* (yr)	1.7 ± 1.9 (0.1-15.0)	1.7 ± 2.0 (0.1-15.0)
Work-related accident (no. [%])	68 (23.6)	49 (23.3)
Profession (no. [%])		
Sedentary	84 (29.2)	52 (24.8)
Light manual	92 (31.9)	73 (34.8)
Heavy manual	75 (26.0)	56 (26.7)
Repetitive	33 (11.5)	25 (11.9)
Unknown	4 (1.4)	4 (1.9)

*The values are given as the mean and the standard deviation, with the range in parentheses.

TABLE II Clinical and Radiographic Preoperative Assessment and Case Notes

	Supraspinatus Tears (N = 288)
Preoperative clinical assessments	
Passive forward elevation* (deg)	166.7 ± 15.6 (90-180)
Active forward elevation* (deg)	148.0 ± 31.3 (40-180)
Contralateral shoulder (no. [%])	
Normal	185 (64.2)
Painful	53 (18.4)
Rotator cuff tear	50 (17.4)
Preoperative radiographic assessments (no. [%])	
Acromial spur	155 (53.8)
Supraspinatus tendon retraction	
Minor	122 (42.4)
Moderate	68 (23.5)
Severe	10 (3.5)
Unknown	88 (30.6)
Supraspinatus fatty infiltration	
0	101 (35.1)
1	88 (30.6)
2	17 (5.9)
3	1 (0.3)
Unknown	81 (28.1)
Intraoperative assessments (no. [%])	
Surgical technique	
Arthroscopy	175 (60.8)
Open	113 (39.2)
Acromioplasty	273 (94.8)
Long head of the biceps	
Normal	127 (44)
Pathologic	129 (44.8)
Unknown	32 (11.1)
Adjuvant procedures on long head of biceps	
None	126 (43.8)
Tenodesis	92 (31.9)
Tenotomy	58 (20.1)
Unknown	12 (4.2)

*The values are given as the mean and the standard deviation, with the range in parentheses.

Of the original cohort of 511 patients, 188 could not be reached and 35 were excluded because they had a reoperation, including repair of a retear in 17, conversion to shoulder arthroplasty in 7, and an operation for other reasons in 11 (Fig. 1). This left a study cohort of 288 patients (50% were men) who had a mean age (and standard deviation) of 56.5 ± 8.3 years (range, 32 to 77 years) at the time of the surgery and were examined clinically (Table I). Of the study cohort, 78 patients were unable or unwilling to be evaluated radiographically, so only 210 patients (49% of whom were men), with a mean age of 56.1 ± 7.6 years (range, 32 to 77 years), were evaluated using magnetic resonance imaging (MRI) as well as frontal and sagittal radiographs made in neutral rotation.

Surgical Techniques

The repair was open (anterosuperior approach) in 113 shoulders (39%) and arthroscopic in 175 shoulders (61%). Adjuvant acromioplasty was performed in 273 shoulders (95%), while biceps tenodesis or tenotomy was performed in 92 (32%) and 58 shoulders (20%), respectively. All tendons were repaired using a single row of suture anchors (149 anchor screws, including 116 that were metallic and 33 that were resorbable), interference fit anchors (34, including 16 that were metallic and 18 that were resorbable), or transosseous repairs (83 shoulders, with material unspecified in 22 shoulders). All repairs were "watertight" at the end of the intervention.

Postoperative Rehabilitation

Following surgery, the arm was supported in a sling with the arm at the side (n = 138) or at 20° of abduction (n = 150) for a mean of 5.6 ± 1.0 weeks (median, 6 weeks; range, 1 to 8 weeks). All centers followed the same rehabilitation protocol, with passive-motion exercises initiated on the first postoperative day, and when possible, hydrotherapy after skin healing. Active shoulder motion was allowed after a mean of 8.2 ± 6.8 weeks (median, 6 weeks; range, 3 to 50 weeks). Patients were not allowed to perform any strengthening or strenuous work for 6 months after the surgery. Light sports and demanding activities were allowed after 6 months.

Postoperative Evaluation

This study cohort of 288 patients were evaluated clinically using the Constant-Murley score³⁶, Subjective Shoulder Value (SSV)^{37,38}, and Subjective Shoulder Test (SST)³⁹. The Constant score was assessed before surgery and at the time of the final follow-up. The subgroup of 210 patients who attended radiographic assessments were evaluated using MRI as well as frontal and sagittal radiographs with the arm in neutral rotation following the imaging protocol described by Walch et al.⁴⁰. In those patients, MRI scans were used to assess tendon healing, according to the Sugaya classification⁴¹, and fatty infiltration, according to the modified Goutallier classification^{42,43}, while radiographs were used to grade glenohumeral arthritis, following the classification described by Samilson and Prieto⁴⁴, and the subacromial space, as described by Walch et al.⁴⁰ (which was considered pathologic if ≤6 mm). The MRI protocol included (1) T2-weighted fat-suppression sequences (non-proton-density-weighted) in the oblique coronal, oblique sagittal, and transverse planes, including the entire scapula, which was used to analyze tendon healing, and (2) T1-weighted sequences in the transverse and sagittal planes, which were used to analyze fatty infiltration and muscle conditions.

Each MRI scan was interpreted by 3 observers, including a senior radiologist, a senior surgeon, and a junior surgeon, all of whom were blinded to patient information. To determine intraobserver and interobserver agreement, each observer repeated his or her readings on 50 MRI scans after an interval of 3 weeks. The Cohen κ statistic test revealed good intraobserver agreement (κ = 0.71) and moderate interobserver agreement (κ = 0.56) for the Goutallier classification⁴², modified by Fuchs et al.⁴³, of fatty infiltration. The κ statistic test revealed good intraobserver agreement (κ = 0.74) and moderate interobserver agreement (κ = 0.68) for the Sugaya classification of tendon healing. In view of unsatisfactory agreement for some variables, discrepancies in classification or grading were discussed by the observers to reach a consensus.

Preoperative MRI scans were available for 207 shoulders (Table II) and revealed fatty infiltration of the supraspinatus at stage 0 in 101 shoulders (35%), stage 1 in 88 (31%), stage 2 in 17 (6%), and stage 3 in 1 (0.3%). The images also revealed tendon retraction to be minor in 122 shoulders (42%), moderate in 68 (24%), and severe in 10 (3%), according to the classification of Patte⁴⁵.

Statistical Analysis

Descriptive statistics were used to summarize the data. For non-Gaussian quantitative data, between-group differences were evaluated using Mann-Whitney U tests. When ≥3 groups were compared, Kruskal-Wallis tests were used. Categorical data were analyzed using Pearson chi-square tests or Fisher exact tests. Univariable and multivariable linear (for Constant scores) and ordinal (for Sugaya type) regression analyses were performed to identify factors

TABLE III Postoperative Assessments

	Preop.*	Postop.*
Complications (no. [%])		
Total complications		30 (10.4)
Infection		1 (0.3)
Stiffness		20 (6.9)
Other		9 (3.1)
Constant score† (points)		
Pain	5.3 ± 3.1 (0-15)	13.0 ± 3.0 (0-15)
Activity	10.2 ± 3.1 (3-19)	17.9 ± 2.9 (5-20)
Mobility	29.4 ± 7.8 (6-40)	35.5 ± 5.8 (6-40)
Strength	6.9 ± 5.4 (0-24)	11.2 ± 5.7 (0-25)
Total Constant score	51.8 ± 13.6 (19-87)	77.7 ± 12.1 (37-100)
Sugaya classification (no. [%])		
I		26 (12.4)
II		85 (40.5)
III		59 (28.1)
IV		27 (12.9)
V		13 (6.2)
Unknown		78 (37.1)
SSV†		84.9 ± 14.8 (20-100)
SST†		10.1 ± 2.2 (3.0-12.0)

*Data were available for 288 patients with respect to the preoperative and postoperative Constant score and complications and for 210 patients with respect to the Sugaya classification. †The values are given as the mean and the standard deviation, with the range in parentheses.

TABLE IV Clinical Outcomes in Relation to Preoperative and Postoperative Fatty Infiltration

	No. (%)	Postop. Constant Score* (points)		
		Total	Strength Component	Pain Component
Preop. fatty infiltration stage (n = 288)				
0	101 (35.1)	80.1 ± 11.8 (47-100)	11.9 ± 6.1 (2-25)	13.6 ± 2.6 (5-15)
1	88 (30.6)	77.3 ± 10.3 (47-97)	10.7 ± 5.3 (0-24)	12.9 ± 3.3 (0-15)
2	17 (5.9)	72.1 ± 13.6 (46-95)	8.9 ± 5.8 (2-22)	11.4 ± 3.5 (5-15)
3	1 (0.3)	78.0 ± 0.0 (78-78)	4.0 ± 0.0 (4-4)	15.0 ± 0.0 (15-15)
Unknown	81 (28.1)	76.3 ± 13.4 (37-100)	11.6 ± 5.6 (0-25)	12.9 ± 2.9 (5-15)
P value		<0.001	0.467	0.926
Postop. fatty infiltration stage (n = 210)				
0	7 (3.3)	89.4 ± 5.4 (84-98)	16.6 ± 5.9 (11-25)	15.0 ± 0.0 (15-15)
1	83 (39.5)	82.1 ± 11.5 (50-100)	13.7 ± 6.2 (2-25)	13.1 ± 2.6 (5-15)
2	92 (43.8)	77.7 ± 11.4 (46-100)	10.3 ± 4.7 (2-25)	12.8 ± 3.0 (5-15)
3	16 (7.6)	68.2 ± 14.7 (44-90)	6.9 ± 3.3 (2-14)	11.4 ± 4.0 (5-15)
4	5 (2.4)	68.8 ± 5.9 (61-75)	4.6 ± 2.4 (2-8)	11.2 ± 2.4 (9-15)
Unknown	7 (3.3)	73.4 ± 10.7 (59-90)	8.0 ± 6.1 (0-18)	13.1 ± 2.4 (10-15)
P value		0.013	<0.001	0.485

*The values are given as the mean and the standard deviation, with the range in parentheses.

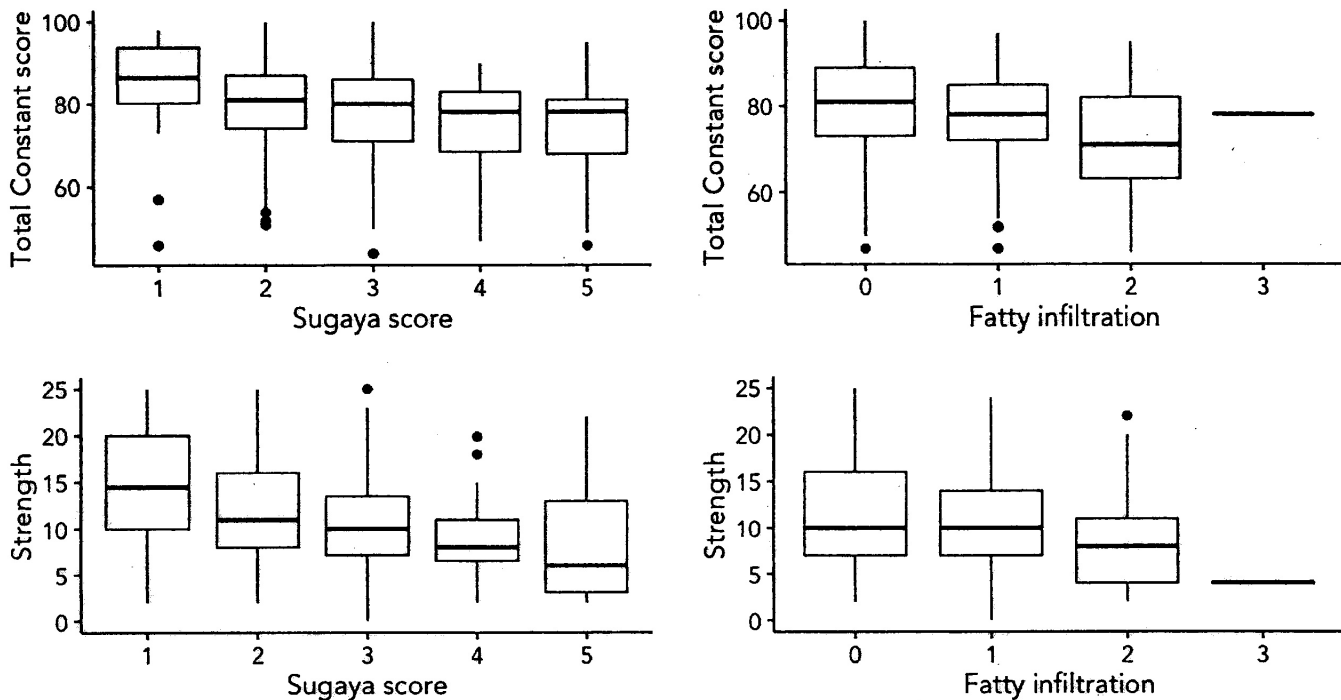


Fig. 2
Boxplots illustrating the Constant score and its strength component for shoulders at different stages of fatty infiltration preoperatively and with different repair integrities at the 10-year follow-up. The boxes indicate the interquartile range, the lines within the boxes indicate the median, and the whiskers indicate the 95% confidence interval. The black circles represent outliers.

associated with the outcomes. The factors considered were patient age, sex, preoperative fatty infiltration, extent of tendon retraction, chronicity of symptoms, occupational injuries, onset of the tear (chronic versus traumatic), level of activity, smoking habits, and surgical approach (open or arthroscopic). A p value of <0.05 was considered significant.

Results

Of the 323 patients who responded, 35 (11%) were excluded because they had a reoperation: 17 (5%), for painful retears of the supraspinatus; 7 (2%), for conversion to shoulder arthroplasty; and 11 (3%), for other reasons. In the remaining 288 shoulders, early complications were noted in 30 (10%), which included stiffness (a deficit of >30° in external

rotation and passive forward elevation compared with the intact, contralateral shoulder) in 20 shoulders, infection in 1, and other complications in 9 (Table III).

In the 288 shoulders evaluated clinically, the mean total Constant score had improved from 51.8 ± 13.6 points (range, 19 to 87 points) preoperatively to 77.7 ± 12.1 points (range, 37 to 100 points) at 10 years. The mean postoperative SSV was 84.9 ± 14.8 (range, 20 to 100), and the mean postoperative SST was 10.1 ± 2.2 (range, 3 to 12). The postoperative Constant score was most significantly associated inversely with preoperative fatty infiltration of the supraspinatus (p < 0.001; chi-square) (Table IV, Fig. 2), although only 1 shoulder was at stage 3 and none were at stage 4. The mean postoperative Constant

TABLE V Clinical Outcomes in Relation to Preoperative Tendon Retraction

Preop. Tendon Retraction	No. (%)	Postop. Constant Score*		
		Total	Strength Component	Pain Component
Minor	122 (42.4)	76.9 ± 11.3 (46-100)	10.5 ± 5.7 (0-25)	13.1 ± 3.2 (0-15)
Moderate	68 (23.6)	78.7 ± 12.8 (37-100)	12.5 ± 5.5 (0-25)	13.6 ± 2.7 (5-15)
Severe	10 (3.5)	83.2 ± 12.7 (56-100)	14.6 ± 6.9 (7-25)	15.0 ± 0.0 (15-15)
Unknown	88 (30.6)	77.4 ± 12.3 (44-96)	11.0 ± 5.7 (2-25)	12.4 ± 3.0 (5-15)
P value		0.193	0.659	0.161

*The values are given as the mean and the standard deviation, with the range in parentheses.

TABLE VI Clinical Outcomes in Relation to Postoperative Repair Integrity (Tendon Healing)

Sugaya Classification	No. (%)	Postop. Constant Score* (points)		
		Total	Strength Component	Pain Component
I	26 (12.4)	84.6 ± 12.2 (46-98)	15.0 ± 6.9 (2-25)	13.5 ± 2.5 (7-15)
II	85 (40.5)	80.1 ± 10.8 (51-100)	12.0 ± 5.5 (2-25)	12.8 ± 3.1 (5-15)
III	59 (28.1)	76.7 ± 13.5 (44-100)	11.1 ± 5.7 (0-25)	12.8 ± 2.9 (5-15)
IV	27 (12.9)	75.5 ± 10.2 (47-90)	8.5 ± 3.9 (2-18)	13.0 ± 2.7 (5-15)
V	13 (6.2)	73.8 ± 14.3 (46-95)	8.1 ± 6.2 (2-22)	12.7 ± 3.1 (5-15)
P value		<0.005	<0.001	0.492

*The values are given as the mean and the standard deviation, with the range in parentheses.

score was lower for women (74.5 ± 11.3 points; range, 37 to 100 points) than for men (80.9 ± 11.9 points; range, 46 to 100 points) ($p < 0.001$), and was slightly lower for work-related tears (74.8 ± 13.3 points; range, 44 to 96 points) than for nonoccupational tears (78.6 ± 11.7 points; range, 37 to 100 points) ($p = 0.027$). The postoperative Constant score was not significantly correlated, however, with preoperative tendon

retraction (Table V), patient age, history of trauma, or surgical approach (open or arthroscopic).

Of the 210 shoulders evaluated using MRI, 26 (12%) had Sugaya type-I repair integrity, 85 (41%) had type II, 59 (28%) had type III, 27 (13%) had type IV, and 13 (6%) had type V. The total Constant score ($p < 0.005$), particularly the strength component ($p < 0.001$), was significantly associated with repair

TABLE VII Literature Review

Study	Approach*	Indications and/or Technique	No. of Patients	Mean Age (yr)	Mean Follow-up Period (yr)
Present study (2017)	A or O		288	56.5	11.0
Kukkonen et al. ³² (2015)	N	Physiotherapy only	55	64.0	2.0
	A	Acromioplasty and physiotherapy	58	65.0	2.0
	A	Rotator cuff repair, acromioplasty, and physiotherapy	54	65.0	2.0
McCormick et al. ²⁷ (2014)	A	Single-row	20	62.5	5.2
	A	Double-row	21	54.3	3.9
	A	Transosseous equivalent	22	61.8	3.1
Nich et al. ²⁹ (2014)	O	Isolated complete detachment of the SSP	27	58.4	8.6
Vastamäki et al. ³⁰ (2013)	O		67	52.0	20.0
Djhangiri et al. ⁴ (2013)	A or O		44	69.0	4.8
Fucntese et al. ²⁴ (2012)	N	Nonop. treatment	24	52.0	3.5
Meyer et al. ²⁸ (2012)	A or O		33	58.0	2.0
Ikemoto et al. ²⁶ (2012)	A	Small and medium-sized SSP tears	129	55.0	3.3
Gerhardt et al. ²⁵ (2012)	A	Single-row modified Mason-Allen repair	20	61.5	1.4
	A	Double-row suture bridge	20	61.2	2.0
Voigt et al. ³¹ (2010)	A	Suture-bridging technique	51	62.0	2.0
Liem et al. ⁵⁰ (2007)	A	Arthroscopic	19	61.9	2.1
	O	Mini-open	19	62.1	1.5
Liem et al. ²¹ (2007)	A		53	60.9	2.2
Boileau et al. ²³ (2005)	A	Tension-band suture technique	65	60.0	2.4

*A = arthroscopy, O = open, and N = nonoperative.

integrity (Table VI, Fig. 2). Retears (types IV and V) were significantly more frequent in patients who were >65 years old (8 [32%] of 25 patients) than in those who were 55 to 65 years old (18 [20%] of 91) and those who were <55 years old (14 [15%] of 94) ($p = 0.040$). Retears were not significantly more frequent in patients who reported shoulder stiffness in the 6 months following their operation (4 [24%] of 17) compared with patients who had no stiffness (36 [19%] of 193). It is worth noting, however, that of the 288 patients who were clinically evaluated, very few patients had repair of acute traumatic tears (5 patients had operative treatment within 3 months after the injury, and 6 patients had operative treatment from 3 to 6 months after the injury). Retears were not significantly more frequent after open repair (19 [25%] of 77 patients) than after arthroscopic repair (21 [16%] of 133 patients) ($p = 0.063$).

The postoperative fatty infiltration of the supraspinatus was stage 0 in 7 shoulders (3%), stage 1 in 83 (40%), stage 2 in 92 (44%), stage 3 in 16 (8%), and stage 4 in 5 (2%). The prevalence of retears (Sugaya type IV or V) was significantly greater in shoulders with postoperative fatty infiltration at stages 3 to 4 (14 [67%] of 21) compared with those with fatty infiltration at stages 0 to 2 (25 [14%] of 182).

Ten-year radiographs were available for 197 patients. They revealed glenohumeral arthritis, according to the Samilson classi-

fication, at stage 0 in 101 shoulders (51%), stage 1 in 72 (37%), stage 2 in 19 (10%), stage 3 in 3 (2%), and stage 4 in 2 shoulders (1%). They also revealed a mean subacromial space of 8.6 ± 2.3 mm (median, 9 mm range, 2 to 16 mm), which was ≤ 6 mm in 29 shoulders (15%).

Multivariable regression analysis revealed no additional significant associations between other independent variables (extent of retraction, fatty infiltration, chronicity of symptoms, occupational injuries, level of activity, and smoking habits) and outcomes measures (Constant score and Sugaya classification of tendon healing).

Discussion

The principal finding of this study was that, 10 years following repair of isolated supraspinatus tears, the Constant score was on average 26 points higher than the preoperative score. This improvement markedly exceeds the minimal clinically important difference (MCID) established for this scoring system⁴⁶. For the patients evaluated using MRI, 81.0% of tendons had healed (Sugaya types I, II, or III), although only 12% had perfect integrity (Sugaya type I). The total Constant score, and particularly its strength component, were significantly correlated with repair integrity at 10 years. The hypothesis that surgical repair of isolated

TABLE VII (continued)

Mean Constant Score			Mean SSV			Mean SST		
Preop.	Postop.	Improvement (%)	Preop.	Postop.	Improvement (%)	Preop.	Postop.	Improvement (%)
51.8	77.7	50		85			10.1	
57.8	76.2	32						
59.6	80.1	34						
58.0	80.6	39						
	72.0					3.1	10.1	(229)
	78.0					2.2	9.3	(315)
	76.0					2.4	10.2	(329)
56.0	76.0	36						
	64.3							
49.0	78.0	59	42	83	(97.6)			
	75.0			74			8.0	
							8.0	
	82.2			91				
	77.0			93				
58.0	88.0	52					12.0	
53.8	83.9	56						
53.5	83.7	56						
53.5	83.4	56						
51.6	83.8	62						

supraspinatus tears would maintain considerable improvement with respect to clinical scores and healing is therefore supported.

Our analysis demonstrated that the total Constant score at 10 years was inversely associated with preoperative fatty infiltration of the supraspinatus but was not significantly associated with preoperative tendon retraction. This finding is consistent with previous studies that showed that preoperative fatty infiltration significantly influenced the outcomes of rotator cuff repairs⁴⁷⁻⁴⁹, whereas minor or moderate preoperative tendon retraction had little effect²⁸. The prevalence of severe retractions in our series was only 3.5%, which could explain why this variable did not correlate with outcomes.

A number of studies have described outcomes following repair of isolated supraspinatus tears^{4,21,23-32,50} (Table VII). The cohort sizes of the former studies ranged from 19 to 67 shoulders, with the exception of the study by Ikemoto et al.²⁶ (129 shoulders), while their follow-up periods were between 1.4 to 5.2 years, with the exception of the studies by Vastamäki et al.³⁰ (20 years) and Nich et al.²⁹ (8.6 years). The total (absolute) Constant score, which was the most frequently reported clinical outcome (11 of 13 studies)^{4,21,23-25,27,29-32,50}, was generally higher in studies with short-term follow-up^{21,23-25,27,31,50} than in those with long-term follow-up^{29,30}. This trend could be related to gradual loss of shoulder strength with advancing age and could have been less marked if scores were age and sex-adjusted^{51,52}.

The 10-year absolute Constant score from the present series was a mean of 77.7 ± 12.1 points, which is within the range reported in the literature. The mean improvement at 10 years was 26 points, despite an expected decrease of the total (absolute) Constant score with age. Moreover, our 10-year results indicated a 50% improvement in the score, which compares favorably with most published studies describing improvement between 32% and 62%^{4,21,23,29,31,32,50}.

There is little consensus on the optimal strategy to manage isolated supraspinatus tears because of the lack of literature describing long-term outcomes with sizeable cohorts^{24,34,35}. On the one hand, Ikemoto et al.²⁶ reported outcomes of 129 supraspinatus repairs, with follow-up limited to 3.3 years, and found good or excellent functional improvements in 90% of the shoulders, with retears in only 3.1%. On the other hand, Vastamäki et al.³⁰ reported outcomes of 67 patients at 20 years, and found relatively poor Constant scores (a mean of 64.3 points), with complete retears in most shoulders (a prevalence of 94%). More recently, Nich et al.²⁹ reported outcomes for 27 supraspinatus repairs at 8.6 years, with good absolute Constant scores (a mean of 76 points) and retears in 17.4%, both of which are comparable with our findings.

In a recent randomized controlled trial, Kukkonen et al.³² reported comparable 2-year clinical outcomes for isolated supraspinatus tears treated by 3 methods: (1) physiotherapy only; (2) acromioplasty and physiotherapy; and (3) repair, acromioplasty, and physiotherapy. While the study has a high level of evidence (Level I), with an adequate sample size in each group, longer follow-up is necessary before recommending physiotherapy or acromioplasty alone for the management of isolated supraspinatus tears. More importantly, the findings of Kukkonen et al.³² may be valid only in older patients, as the average age in their series was 65 years (range, 55 to 81 years). There is evidence that patient expectations,

functional demands, and healing capabilities of the rotator cuff vary depending on age^{22,53,54}. In the present series, the rate of retears was significantly higher (32%) for patients who were >65 years old than in those who were 55 to 65 years old (20%) or <55 years old (15%). This trend corroborates the observations of Yamaguchi⁵⁴, which are important to consider in the treatment of rotator cuff tears, as surgical repair is increasingly performed in younger patients to prevent tear propagation and tissue degeneration.

The main strength of the present study is the investigation of the structural and functional outcome at longer-term follow-up after repair of isolated supraspinatus tears. Our data therefore enabled reliable analysis of repair integrity and longevity. The study has limitations typical of retrospective investigations that relate to selection bias, including the large proportion of patients lost to follow-up (37%) and the exclusion of patients who had a reoperation or did not have follow-up MRI. The effects of heterogeneity of the repair techniques (suture techniques and anchor materials used) and postoperative management were not evaluated.

In conclusion, clinical evaluation reveals that surgical repair of isolated supraspinatus tears maintained considerable improvements with respect to the absolute Constant score. At long-term follow-up, functional outcome as assessed by the Constant score is significantly compromised by preoperative fatty infiltration and by retear. ■

NOTE: The authors thank Dr. Gerjon Hannink for his assistance with the statistical analysis and Mr. Luca Nover for his help with preparation of the manuscript, tables, and figures.

Philippe Collin, MD¹
Jean-François Kempf, MD, PhD²
Daniel Molé, MD³
Nicolas Meyer, PhD⁴
Charles Agout, MD⁵
Mo Saffarini, MEng⁶
Arnaud Godenèche, MD⁷
and the Société Française de Chirurgie Orthopédique et Traumatologique (SoFCOT)⁸

¹CHP Saint Grégoire VIVALTO Santé, Saint Grégoire, France

²Centre Chirurgical Émile Gallé, Nancy, France

³Centre de Traumatologie, Hôpitaux Universitaires de Strasbourg, Illkirch-Graffenstaden, France

⁴Laboratoire de Bio Statistiques, Faculté de Médecine de l'Université de Strasbourg, Strasbourg CEDEX, France

⁵Service de Chirurgie Orthopédique et Traumatologique Hôpital Trousseau CHRU, Tours, France

⁶ReSurg SA, Nyon, Switzerland

⁷Centre Orthopédique Santy, Hôpital Privé Jean Mermoz (Ramsay Générale de Santé), Lyon, France

⁸SoFCOT, Paris, France

E-mail address for P. Collin: collin.ph@wanadoo.fr

References

1. Fehring EV, Sun J, VanOeveren LS, Keller BK, Matsen FA 3rd. Full-thickness rotator cuff tear prevalence and correlation with function and co-morbidities in patients sixty-five years and older. *J Shoulder Elbow Surg.* 2008 Nov-Dec;17(6):881-5. Epub 2008 Sep 6.
2. Sher JS, Uribe JW, Posada A, Murphy BJ, Zlatkin MB. Abnormal findings on magnetic resonance images of asymptomatic shoulders. *J Bone Joint Surg Am.* 1995 Jan;77(1):10-5.
3. Tempelhof S, Rupp S, Seil R. Age-related prevalence of rotator cuff tears in asymptomatic shoulders. *J Shoulder Elbow Surg.* 1999 Jul-Aug;8(4):296-9.
4. Djangiri A, Cozzolino A, Zanetti M, Helmy N, Rufibach K, Jost B, Gerber C. Outcome of single-tendon rotator cuff repair in patients aged older than 65 years. *J Shoulder Elbow Surg.* 2013 Jan;22(1):45-51. Epub 2012 Jun 26.
5. Seidler A, Bolm-Audorff U, Petereit-Haack G, Ball E, Klupp M, Krauss N, Eisner G. Work-related lesions of the supraspinatus tendon: a case-control study. *Int Arch Occup Environ Health.* 2011 Apr;84(4):425-33. Epub 2010 Aug 25.
6. Genuario JW, Donegan RP, Hamman D, Bell JE, Boublik M, Schlegel T, Tosteson AN. The cost-effectiveness of single-row compared with double-row arthroscopic rotator cuff repair. *J Bone Joint Surg Am.* 2012 Aug 1;94(15):1369-77.
7. Mather RC 3rd, Koenig L, Acevedo D, Dall TM, Gallo P, Romeo A, Tongue J, Williams G Jr. The societal and economic value of rotator cuff repair. *J Bone Joint Surg Am.* 2013 Nov 20;95(22):1993-2000.
8. Yamaguchi K, Tetro AM, Blam O, Evanoff BA, Teeffey SA, Middleton WD. Natural history of asymptomatic rotator cuff tears: a longitudinal analysis of asymptomatic tears detected sonographically. *J Shoulder Elbow Surg.* 2001 May-Jun;10(3):199-203.
9. Moosmayer S, Tariq R, Stiris M, Smith HJ. The natural history of asymptomatic rotator cuff tears: a three-year follow-up of fifty cases. *J Bone Joint Surg Am.* 2013 Jul 17;95(14):1249-55.
10. Bey MJ, Ramsey ML, Soslosky LJ. Intratendinous strain fields of the supraspinatus tendon: effect of a surgically created articular-surface rotator cuff tear. *J Shoulder Elbow Surg.* 2002 Nov-Dec;11(6):562-9.
11. Bey MJ, Song HK, Wehrli FW, Soslosky LJ. Intratendinous strain fields of the intact supraspinatus tendon: the effect of glenohumeral joint position and tendon region. *J Orthop Res.* 2002 Jul;20(4):869-74.
12. Keener JD, Wei AS, Kim HM, Steger-May K, Yamaguchi K. Proximal humeral migration in shoulders with symptomatic and asymptomatic rotator cuff tears. *J Bone Joint Surg Am.* 2009 Jun;91(6):1405-13.
13. Kim HM, Dahiya N, Teeffey SA, Middleton WD, Stobbs G, Steger-May K, Yamaguchi K, Keener JD. Location and initiation of degenerative rotator cuff tears: an analysis of three hundred and sixty shoulders. *J Bone Joint Surg Am.* 2010 May;92(5):1088-96.
14. Moosmayer S, Tariq R, Stiris MG, Smith HJ. MRI of symptomatic and asymptomatic full-thickness rotator cuff tears. A comparison of findings in 100 subjects. *Acta Orthop.* 2010 Jun;81(3):361-6.
15. Reilly P, Amis AA, Wallace AL, Emery RJ. Mechanical factors in the initiation and propagation of tears of the rotator cuff. Quantification of strains of the supraspinatus tendon in vitro. *J Bone Joint Surg Br.* 2003 May;85(4):594-9.
16. Reilly P, Amis AA, Wallace AL, Emery RJ. Supraspinatus tears: propagation and strain alteration. *J Shoulder Elbow Surg.* 2003 Mar-Apr;12(2):134-8.
17. Gerber C, Meyer DC, Nuss KM, Farshad M. Anabolic steroids reduce muscle damage caused by rotator cuff tendon release in an experimental study in rabbits. *J Bone Joint Surg Am.* 2011 Dec 7;93(23):2189-95.
18. Goutallier D, Postel JM, Lavau L, Bernageau J. [Impact of fatty degeneration of the supraspinatus and infraspinatus muscles on the prognosis of surgical repair of the rotator cuff]. *Rev Chir Orthop Reparatrice Appar Mot.* 1999 Nov;85(7):668-76. French.
19. Mall NA, Kim HM, Keener JD, Steger-May K, Teeffey SA, Middleton WD, Stobbs G, Yamaguchi K. Symptomatic progression of asymptomatic rotator cuff tears: a prospective study of clinical and sonographic variables. *J Bone Joint Surg Am.* 2010 Nov 17;92(16):2623-33.
20. Gerber C, Meyer DC, Frey E, von Rechenberg B, Hoppeler H, Frigg R, Jost B, Zumstein MA. Neer Award 2007: Reversion of structural muscle changes caused by chronic rotator cuff tears using continuous musculotendinous traction. An experimental study in sheep. *J Shoulder Elbow Surg.* 2009 Mar-Apr;18(2):163-71. Epub 2008 Dec 18.
21. Liem D, Lichtenberg S, Magosch P, Habermeyer P. Magnetic resonance imaging of arthroscopic supraspinatus tendon repair. *J Bone Joint Surg Am.* 2007 Aug;89(8):1770-6.
22. Yamaguchi K, Ditsios K, Middleton WD, Hildebolt CF, Galatz LM, Teeffey SA. The demographic and morphological features of rotator cuff disease. A comparison of asymptomatic and symptomatic shoulders. *J Bone Joint Surg Am.* 2006 Aug;88(8):1699-704.
23. Boileau P, Brassart N, Watkinson DJ, Carles M, Hatizidakis AM, Krishnan SG. Arthroscopic repair of full-thickness tears of the supraspinatus: does the tendon really heal? *J Bone Joint Surg Am.* 2005 Jun;87(6):1229-40.
24. Fucetese SF, von Roll AL, Pfirrmann CW, Gerber C, Jost B. Evolution of non-operatively treated symptomatic isolated full-thickness supraspinatus tears. *J Bone Joint Surg Am.* 2012 May 2;94(9):801-8.
25. Gerhardt C, Hug K, Pauly S, Marnitz T, Scheibel M. Arthroscopic single-row modified mason-allen repair versus double-row suture bridge reconstruction for supraspinatus tendon tears: a matched-pair analysis. *Am J Sports Med.* 2012 Dec;40(12):2777-85. Epub 2012 Oct 26.
26. Ikemoto RY, Murachovsky J, Nascimento LG, Bueno RS, Almeida LH, Stroze E, Castiglia MT. Arthroscopic repair of small and medium tears of the supraspinatus muscle tendon: evaluation of the clinical and functional outcomes after two years of follow-up. *Rev Bras Ortop.* 2012 Jul-Aug;47(4):436-40.
27. McCormick F, Gupta A, Bruce B, Harris J, Abrams G, Wilson H, Hussey K, Cole BJ. Single-row, double-row, and transosseous equivalent techniques for isolated supraspinatus tendon tears with minimal atrophy: a retrospective comparative outcome and radiographic analysis at minimum 2-year followup. *Int J Shoulder Surg.* 2014 Jan;8(1):15-20.
28. Meyer DC, Wieser K, Farshad M, Gerber C. Retraction of supraspinatus muscle and tendon as predictors of success of rotator cuff repair. *Am J Sports Med.* 2012 Oct;40(10):2242-7. Epub 2012 Aug 27.
29. Nich C, Dhiaf N, Di Schino M, Augereau B. Does partial tear repair of adjacent tendons improve the outcome of supraspinatus tendonfull-thickness tear reinsertion? *Orthop Traumatol Surg Res.* 2014 Nov;100(7):721-6. Epub 2014 Oct 3.
30. Vastamäki M, Lohman M, Borgmästars N. Rotator cuff integrity correlates with clinical and functional results at a minimum 16 years after open repair. *Clin Orthop Relat Res.* 2013 Feb;471(2):554-61. Epub 2012 Aug 16.
31. Voigt C, Bosse C, Vosschenrich R, Schulz AP, Lill H. Arthroscopic supraspinatus tendon repair with suture-bridging technique: functional outcome and magnetic resonance imaging. *Am J Sports Med.* 2010 May;38(5):983-91.
32. Kukkonen J, Joukainen A, Lehtinen J, Mattila KT, Tuominen EK, Kauko T, Äärinmaa V. Treatment of nontraumatic rotator cuff tears: a randomized controlled trial with two years of clinical and imaging follow-up. *J Bone Joint Surg Am.* 2015 Nov 4;97(21):1729-37.
33. Moosmayer S, Lund G, Seljom US, Haldorsen B, Svege IC, Hennig T, Pripp AH, Smith HJ. Tendon repair compared with physiotherapy in the treatment of rotator cuff tears: a randomized controlled study in 103 cases with a five-year follow-up. *J Bone Joint Surg Am.* 2014 Sep 17;96(18):1504-14.
34. Kukkonen J, Joukainen A, Lehtinen J, Mattila KT, Tuominen EK, Kauko T, Äärinmaa V. Treatment of non-traumatic rotator cuff tears: A randomised controlled trial with one-year clinical results. *Bone Joint J.* 2014 Jan;96-B(1):75-81.
35. Strauss EJ, Salata MJ, Kercher J, Barker JU, McGill K, Bach BR Jr, Romeo AA, Verma NN. Multimedia article. The arthroscopic management of partial-thickness rotator cuff tears: a systematic review of the literature. *Arthroscopy.* 2011 Apr;27(4):568-80.
36. Constant CR, Murley AH. A clinical method of functional assessment of the shoulder. *Clin Orthop Relat Res.* 1987 Jan;214:160-4.
37. Gilbert MK, Gerber C. Comparison of the subjective shoulder value and the Constant score. *J Shoulder Elbow Surg.* 2007 Nov-Dec;16(6):717-21.
38. Gerber C, Fuchs B, Hodler J. The results of repair of massive tears of the rotator cuff. *J Bone Joint Surg Am.* 2000 Apr;82(4):505-15.
39. Roddey TS, Olson SL, Cook KF, Gartsmann GM, Hanten W. Comparison of the University of California-Los Angeles Shoulder Scale and the Simple Shoulder Test with the shoulder pain and disability index: single-administration reliability and validity. *Phys Ther.* 2000 Aug;80(8):759-68.
40. Walch G, Edwards TB, Boualhia A, Nové-Josserand L, Neyton L, Szabo I. Arthroscopic tenotomy of the long head of the biceps in the treatment of rotator cuff tears: clinical and radiographic results of 307 cases. *J Shoulder Elbow Surg.* 2005 May-Jun;14(3):238-46.
41. Sugaya H, Maeda K, Matsuki K, Morishi J. Repair integrity and functional outcome after arthroscopic double-row rotator cuff repair. A prospective outcome study. *J Bone Joint Surg Am.* 2007 May;89(5):953-60.
42. Goutallier D, Postel JM, Bernageau J, Lavau L, Voisin MC. Fatty muscle degeneration in cuff ruptures. Pre- and postoperative evaluation by CT scan. *Clin Orthop Relat Res.* 1994 Jul;304:78-83.
43. Fuchs B, Weishaupt D, Zanetti M, Hodler J, Gerber C. Fatty degeneration of the muscles of the rotator cuff: assessment by computed tomography versus magnetic resonance imaging. *J Shoulder Elbow Surg.* 1999 Nov-Dec;8(6):599-605.
44. Samilson RL, Prieto V. Dislocation arthropathy of the shoulder. *J Bone Joint Surg Am.* 1983 Apr;65(4):456-60. Epub 1983 Apr 1.
45. Patte D. Classification of rotator cuff lesions. *Clin Orthop Relat Res.* 1990 May;254:81-6.
46. Kukkonen J, Joukainen A, Itälä A, Äärinmaa V. Operatively treated traumatic versus non-traumatic rotator cuff ruptures: a registry study. *Ups J Med Sci.* 2013 Mar;118(1):29-34. Epub 2012 Nov 20.
47. Barth J, Fotiadis E, Barthelemy R, Genna S, Saffarini M. Ultrasonic evaluation of the repair integrity can predict functional outcomes after arthroscopic double-row

rotator cuff repair. *Knee Surg Sports Traumatol Arthrosc.* 2015 Feb;23(2):376-85. Epub 2015 Jan 20.

- 48.** Dwyer T, Razmjou H, Henry P, Gosselin-Fournier S, Holtby R. Association between pre-operative magnetic resonance imaging and reparability of large and massive rotator cuff tears. *Knee Surg Sports Traumatol Arthrosc.* 2015 Feb;23(2):415-22. Epub 2013 Oct 30.
- 49.** Shon MS, Koh KH, Lim TK, Kim WJ, Kim KC, Yoo JC. Arthroscopic partial repair of irreparable rotator cuff tears: preoperative factors associated with outcome deterioration over 2 years. *Am J Sports Med.* 2015 Aug;43(8):1965-75. Epub 2015 May 26.
- 50.** Liem D, Bartl C, Lichtenberg S, Magosch P, Habermeyer P. Clinical outcome and tendon integrity of arthroscopic versus mini-open supraspinatus tendon repair: a magnetic resonance imaging-controlled matched-pair analysis. *Arthroscopy.* 2007 May;23(5):514-21.

51. Grassi FA, Tajana MS. The normalization of data in the Constant-Murley score for the shoulder. A study conducted on 563 healthy subjects. *Chir Organi Mov.* 2003 Jan-Mar;88(1):65-73.

- 52.** Katolik LI, Romeo AA, Cole BJ, Verma NN, Hayden JK, Bach BR. Normalization of the Constant score. *J Shoulder Elbow Surg.* 2005 May-Jun;14(3):279-85.
- 53.** Kim HM, Caldwell JM, Buza JA, Fink LA, Ahmad CS, Bigliani LU, Levine WN. Factors affecting satisfaction and shoulder function in patients with a recurrent rotator cuff tear. *J Bone Joint Surg Am.* 2014 Jan 15;96(2):106-12.
- 54.** Yamaguchi K. Initial nonoperative care is reasonable for older patients: commentary on an article by Juha Kukkonen, MD, PhD, et al.: "Treatment of nontraumatic rotator cuff tears. A randomized controlled trial with two years of clinical and imaging follow-up. *J Bone Joint Surg Am.* 2015 Nov 4;97(21):e70.