

Use of Ultrasound-Guided Platelet-Rich Plasma Injection of the Sacroiliac Joint as a Treatment for Chronic Low Back Pain

2d Lt Devin Y. Broadhead, MC USAF; ENS Hannah E. Douglas, MC USN*;
Capt Laurie M. Bezjian Wallace, MC USAF*; Patrick J. Wallace, DO*; Sarah Tamura, MS†;
Kyle C. Morgan, DO†; Col Douglas E. Hemler, MC, FS, USAFR (Ret.)†*

ABSTRACT Back pain and its associated complications are of increasing importance among military members. The sacroiliac joint (SIJ) is a common source of chronic low back pain (LBP) and functional disability. Many patients suffering from chronic LBP utilize opioids to help control their symptoms. Platelet-rich plasma (PRP) has been used extensively to treat pain emanating from many different musculoskeletal origins; however, its use in the SIJ has been studied only on a limited basis. The patient in this case report presented with chronic LBP localized to the SIJ and subsequent functional disability managed with high-dose opioids. After failure of traditional treatments, she was given an ultrasound-guided PRP injection of the SIJ which drastically decreased her pain and disability and eventually allowed for complete opioid cessation. Her symptom relief continued 1 year after the injection. This case demonstrates the potential of ultrasound-guided PRP injections as a long-term treatment for chronic LBP caused by SIJ dysfunction in military service members, which can also aid in the weaning of chronic opioid use.

INTRODUCTION

Back pain is one of the most common reasons why active duty military personnel seek medical care.^{1–3} From 2010 to 2014, low back pain (LBP) diagnoses accounted for 6,268,752 outpatient medical encounters and 25,930 inpatient encounters among active duty members.⁴ Back pain also plays a significant role in combat operations. During Operation Enduring Freedom, musculoskeletal disorders of the back and joints were a major cause of medical evacuation from Afghanistan.⁵ Those who were evacuated from the theater due to LBP had a very low rate of return to their unit.⁶ Moreover, musculoskeletal conditions represent a common reason why service members are placed on limited duty and considered medically not fit to deploy.⁷ Military members with certain occupations, such as motor vehicle operators, are more prone to developing LBP than service members of other occupations.⁸ With such large numbers of active duty service members being restricted in their specified duties and unable to deploy as a result of LBP, the mission of the Department of Defense as well as workflow throughout the military can be greatly affected. Up to 75% of active duty pilots will experience back pain during their career.⁹ Significant time, money, and resources are utilized in training active duty members in the aviation community, and each day away from work affects the exe-

cution of the military's mission. As such, accurate diagnosis and effective treatment modalities are imperative to increase healing and decrease the time it takes to return to work duties. Furthermore, studies have shown musculoskeletal conditions were among the top reasons for medical disability retirement in the Army and Marine Corps.^{10, 11}

Between 15 and 30% of the time, LBP cases are found to have sacroiliac joint (SIJ) etiology.^{12, 13} The SIJ is a well innervated, complex, diarthrodial joint composed of both fibrocartilage and hyaline cartilage in addition to many adjacent stabilizing ligaments and is responsible for load transfer from the spine to the legs.^{14, 15} SIJ dysfunction can be identified by assessing location of the pain, movement and posture of the patient, as well as provocative maneuvers.¹⁶ Typical treatment for active duty service members includes conservative management such as NSAIDs and physical therapy and corticosteroid injections.^{16, 17, 18} A recent study by Singla et al. showed platelet-rich plasma (PRP) injections of the SIJ to be more effective than traditional steroid injections through restoration of joint function and sustained pain relief.¹⁹ As such this new treatment modality is a promising intervention for the treatment of LBP in active duty service members.

Finally, physicians managing musculoskeletal and spine conditions are frequently called upon to co-manage patients utilizing long-term opioids. Opioids are the most commonly prescribed pain medication in adults suffering from chronic LBP despite limited evidence as to their efficacy.^{20, 21} Over the recent years, opioid use has been increasing in the military population.²² Weaning opioids in many patients is now considered the best medical practice. The call to reduce opioids has occurred at a time when regenerative medicine options are being explored. Currently, there is relatively little information available regarding the treatment of SIJ dysfunction with PRP, especially in patients utilizing high-dose opioids.

*Rocky Vista University College of Osteopathic Medicine, 8401 S. Chambers Rd, Parker, CO 80134, USA

†Star Spine and Sport, 2801 Youngfield St, Suite 150, Golden, CO 80401, USA

The views expressed are solely those of the authors and do not reflect the official policy or position of the US Navy, US Air Force, the Department of Defense, or the US Government.

doi:10.1093/milmed/usz398

© Association of Military Surgeons of the United States 2019. All rights reserved. For permissions, please e-mail: journals.permissions@oup.com.

This case report presents a patient whose SIJ-induced LBP and resultant functional disability were drastically decreased through utilization of ultrasound-guided PRP injection. This ultimately led to complete weaning of high-dose opioids.

CASE REPORT

A 62-year-old female with long-standing right inferior pole SIJ pain presented to a Physical Medicine Musculoskeletal practice. Consistent with traditional treatment regimens of SIJ dysfunction, this patient had previously undergone physical therapy, manual techniques (chiropractic, osteopathic), acupuncture, fluoroscopically guided inter-articular SIJ and epidural steroid injections, and transcutaneous electrical nerve stimulation. These treatments provided moderate but temporary pain relief. The patient performed home exercises and iced the SIJ on a daily basis. Diagnostic imaging included flexion-extension spinal X-rays and a non-contrast MRI of the lumbar spine showing spondylosis with SIJ arthritis. Inflammatory sacroiliitis was previously ruled out.

Key aspects of the physical examination included tenderness at the right lumbar base. The Fortin Finger Test (point of maximal tenderness), FABER, and Gaenslen's test were positive on the right side and negative on the left side. Provocative maneuvers for the zygapophyseal joints, piriformis, femoroacetabular region, and greater trochanter were negative.

On the numeric rating scale (NRS), typical daily pain was 5/10, reaching 9/10 with prolonged sitting.

Upon presentation, the patient was taking approximately 390 morphine milligram equivalents in the form of 30 mg of methadone HCl and morphine sulfate immediate release. Management was initially directed at both incremental reduction of the opioids and treatment of the right SIJ. Initial treatment included an ultrasound-guided injection of the right sacroiliac ligament utilizing a combination of triamcinolone 40 mg and 5 mL of lidocaine 1% and bupivacaine 0.25%. The patient initially reported a concordant pain response, 6/10 dropping to 1/10. Over the course of 5 months, pain was reduced to 3/10 with the use of corticosteroids. Additionally, attempts were made to wean the patient from opioids during this period.

At the 6-month follow-up, the patient reported a return of pain and deterioration in function. A mutual decision was reached to treat the SIJ ligament and joint with PRP. The PRP injection was completed using the method as noted below, administering medication into both the ligament and posterior aspect of the joint capsule.

METHODS

Signed informed consent was obtained prior to the procedure. Autologous PRP was prepared using the Terumo BCT Inc. SmartPREP 3 Platelet Concentrate System per manufacturer's instructions and guidelines. A phlebotomist withdrew 60 mL of whole venous blood from the patient's arm with a 19-gauge $\frac{3}{4}$ inch needle using universal precautions and

mixed with 8 mL of anticoagulant citrate dextrose solution A (ACD-A). The anticoagulated blood was centrifuged for 15 minutes at 3200 RPM to separate plasma from blood cells. The platelet-deficient portion was extracted and discarded, while the platelet-rich layer with buffy coat, to include white blood cells and red blood cells, was remixed. This resulted in approximately 5 mL of PRP. PRP concentrates can range from 5 to 10 times greater than the baseline level of platelets in an average patient's systemic circulation. Ultrasonography (curved probe) in conjunction with the Fortin Finger Test was used to identify the point of injection. The injection site was cleansed with ChlorPrep and injected with 1% lidocaine to anesthetize the skin and subcutaneous tissue. Utilizing ultrasound guidance, a 3" 22G spinal needle was inserted in a medial to lateral fashion with in-plane visualization. Three mL of concentrated PRP was injected into the SIJ and the adjacent soft tissue including the posterior sacroiliac ligament and joint capsule as the needle was withdrawn. The patient was monitored for 15 minutes post-injection for acute complications, in which no adverse effects were observed. The patient's pain was recorded using the NRS and functionality using the Oswestry disability index (ODI) at 2 weeks, 4 weeks, 6 months, 9 months, and 1 year post-injection (Figs. 1 and 2). The percentage of change in the patient's NRS and ODI scores were compared from baseline to 2 weeks, 4 weeks, 6 months, 9 months, and 1 year post-injection.

RESULTS

On the day of the PRP injection, the patient was consuming 180 morphine milligram equivalents (120 mg morphine sulfate immediate release and 15 mg methadone HCl) per day. The patient reported a baseline ODI of 80.00% with an NRS of 8/10. At the 2-week follow-up, the patient's NRS was 9/10 (12.5% increase) and ODI was 84.44% (5.55% increase). At the 4-week follow-up, she had improved to an NRS of 7/10 (12.5% reduction) and an ODI of 68.89% (13.89% reduction). Opioid weaning began 3 months after the procedure. At that time, the patient's NRS was 6/10 (25% reduction) and ODI was 31.11% (61.11% reduction). By the 6-month follow-up, the patient required 80 morphine milligram equivalents (55.56% reduction) with an NRS of 4/10 (50% reduction) and an ODI of 46.67% (41.66% reduction) and reported an improvement in function. The patient was completely weaned from opioids (100% reduction) 9 months after the PRP injection with an NRS of 1/10 (87.5% reduction) and an ODI of 45.22% (43.48% reduction). At 1 year following the procedure, pain relief persisted with an NRS of 1/10 (87.5% reduction) and continual improvement of the patient's ODI score at 35.56% (55.55% reduction), while the patient also maintained opioid independence.

DISCUSSION

PRP has been shown to be successful in treating chronic pain originating from musculoskeletal origin (tendon, ligament,

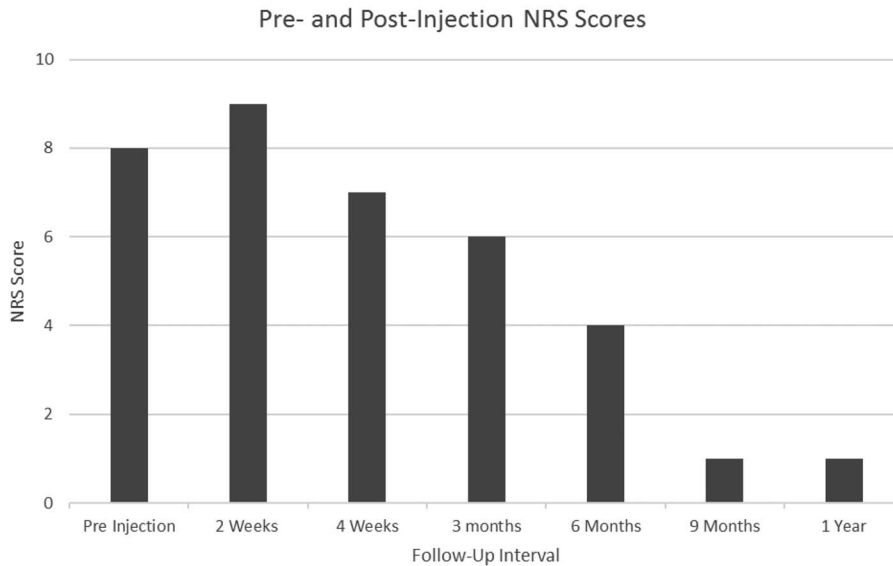


FIGURE 1. Pre- and Post-injection NRS Scores. Comparison of the Patient’s Baseline NRS Score at the Time of Injection with Scores at 2 Weeks, 4 Weeks, 6 Months, 9 Months, and 1 Year Following the Platelet-Rich Plasma (PRP) Injection.

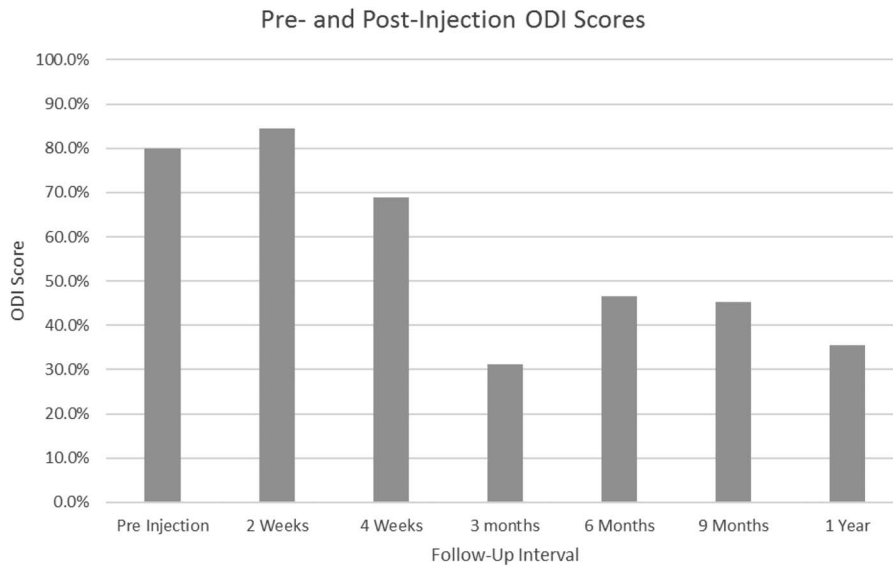


FIGURE 2. Pre- and Post-Injection ODI Scores. Comparison of the Patient’s Baseline ODI Score at the Time of Injection with Scores at 2 Weeks, 4 Weeks, 6 Months, 9 Months, and 1 Year Following the Platelet-Rich Plasma (PRP) Injection.

muscle), joint (shoulder, knee, SIJ), and intervertebral discs.^{19, 23, 24} There is minimal literature investigating the use of PRP at the SIJ. Singla et al. published the only prospective trial to date investigating PRP versus corticosteroid injections in relieving LBP secondary to SIJ dysfunction. This study demonstrated PRP to have a statistically significant decrease in visual analog scale at 6 weeks (median interquartile range = 1 [1–1]) and 3 months (median interquartile range = 1 [1–1]) compared to corticosteroids. However, there was no significant difference at 2 and 4 weeks, suggesting that PRP has the most impact starting at about 1.5–2 months post-injection and has a more long-term effect.¹⁹ With so few studies published, the effects and biochemistry of PRP are still being investigated. Data suggests PRP works via variety

of growth factors, proteins, chemokines, and immunomodulators. These factors are released after platelets are activated and aid in the modulation of an intrinsic proinflammatory cascade and regeneration of the joint.²⁵ Some of these inflammatory markers include fibroblast growth factor, vascular endothelial growth factor, and connective tissue growth factor, all of which contribute to the regeneration of the joint.²⁶

The purpose of this case report was to demonstrate one patient’s substantial improvement following ultrasound-guided PRP injection of the SIJ for LBP. This patient’s NRS decreased from a baseline of 8 to 1 over the course of 9 months, while her ODI dropped from 80% to 45.22%. Previously, corticosteroid injections of the SIJ had only alleviated her pain for 5 months with return of pain and loss of

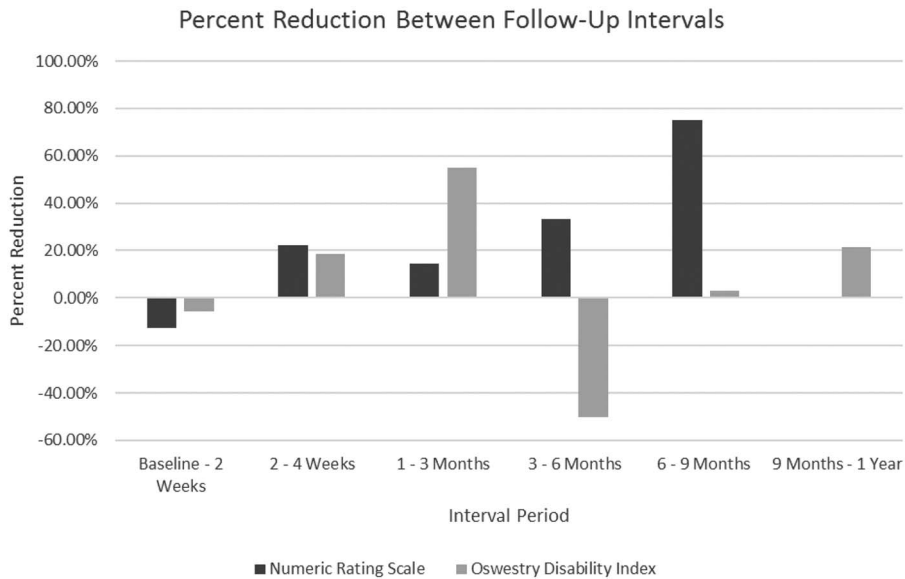


FIGURE 3. Percent Reduction Between Follow-Up Intervals. Comparison of the Percent of Change in the Patient’s NRS and ODI Scores Between Each of the Follow-Up Intervals.

function occurring by the 6-month post-injection. After 1 year, the patient reported further decrease in her ODI to 35.56% and maintenance of NRS at 1. As compared to her other treatments, PRP injection was demonstrated to be superior.

The patient suffered no complications from the PRP injection. She did have a temporary increase in pain at the injection site immediately post procedure, but this has been shown in the past to be a transient effect and common to other similar procedures.^{19, 23} Even though corticosteroid injection does provide temporary reduction in NRS, it comes at the expense of decreasing the body’s ability to heal itself at the site of injection.^{19, 27}

Of note, the patient’s ODI and NRS increased from baseline at the 2-week follow-up. Between the 3-month and 6-month follow-ups, the patient’s NRS continued to decrease, while her ODI increased. The greatest reduction from baseline in the patient’s ODI score occurred at the 3-month mark, while the greatest reduction from baseline in her NRS score happened at the 9-month follow-up and continued to 1 year. The interval that showed the largest reduction in ODI occurred between 1 and 3 months, while the greatest reduction in NRS happened between 6 and 9 months (Fig. 3). The patient did not receive any repeat imaging during the follow-up period. She did continue to experience tenderness in the right lumbosacral area, and Gaenslen’s test as well as FABER test remained positive on the right during follow-up. Provocative maneuvers involving the zygapophyseal lumbar joints, femoroacetabular joints, and piriformis were negative bilaterally throughout the follow-up period. Nevertheless, her progress was determined solely by the NRS and ODI scales.

Considering the dose and duration of our patient’s opioid use, the possibility of opioid-induced hyperalgesia (OIH) had to be considered as a potential confounding factor.

This phenomenon is characterized by a paradoxical increase in the pain experienced by a patient receiving high-dose opioids for chronic pain.²⁸ However, OIH produces a diffuse ill-defined pain that extends to areas apart from the location of the preexisting pain.²⁸ As our patient’s pain remained localized to the SIJ throughout the case, OIH was ultimately ruled out. Additionally, her pain decreased 3 months post PRP injection from a 9 on the NRS to a 6 while she remained on 120 mg of morphine and 15 mg of methadone. Only at that point did she begin to wean off opioids. She was completely weaned from methadone 6 months post-injection with an NRS of 4 and morphine 9 months post-injection with an NRS of 1. At the 1-year mark, her NRS was 1, and she had not taken any opioids for 3 months. Finally, opioid tapering has not been associated with worsening pain²⁹, and any possible hyperalgesia experienced directly after discontinuation is very brief and most likely not reflected in the results of this case considering the length of time between follow-up intervals.

Given its ability to decrease pain and improve functionality, ultrasound-guided PRP injections of the SIJ could potentially help reduce the prevalence of chronic LBP, limited and lost duty days, medical disability retirement, and opioid use disorders in the military, all of which would allow service members to function at a higher level and better perform their duties. Considering that the use of PRP in injured athletes has been shown to oftentimes result in an early return to play^{30, 31}, the employment of the combined technologies of musculoskeletal ultrasound and PRP may lead to an earlier return to duty and reduce delays in recovery. Despite a longer duration of onset, the significant reduction in pain and disability coupled with the sustainability of results makes this intervention promising for active duty service members without

significantly impacting the workflow within the individual's duty sections. Ultimately, the application of SIJ PRP injections as an effective long-term treatment for chronic LBP could prove to be invaluable in maintaining readiness across the active duty population. Further investigation is needed to compare the risks, benefits, and usefulness of treating SIJ-induced LBP with ultrasound-guided PRP injections in larger sample sizes.

CONCLUSION

PRP is becoming progressively understood and utilized by practitioners engaged in the treatment of injuries to tendons, ligaments, cartilage, and bone. In this patient, ultrasound-guided PRP injection of the SIJ provided significant pain relief and increased function for up to 1 year following the procedure. Ultrasound-guided PRP injections show promising results in relieving chronic pain of the SIJ, especially in the active duty military population. Utilizing PRP injections for LBP may help produce sustainable and significant reductions in pain and functional disability which can ultimately lead to a quicker return to duty.

ACKNOWLEDGMENTS

Special thanks to Col (ret.) Anthony LaPorta, Alexis Horst, Hannah Golesh, and Colleen Montoya for their help in making this case report possible.

FUNDING

SmartPRP 3 Platelet Concentrate Systems were donated by Terumo BCT Inc.

REFERENCES

1. Absolute and relative morbidity burdens attributable to various illnesses and injuries, active component: U.S. armed forces, 2017. *MSMR* 2018; 25(5): 2–9.
2. Absolute and relative morbidity burdens attributable to various illnesses and injuries, active component: U.S. armed forces, 2016. *MSMR* 2017; 24(4): 2–8.
3. Absolute and relative morbidity burdens attributable to various illnesses and injuries, active component: U.S. armed forces, 2015. *MSMR* 2016; 23(4): 2–7.
4. Clark LL, Hu Z: Diagnoses of low back pain, active component, U.S. armed forces, 2010–2014. *MSMR* 2015; 22(12): 8–11.
5. Medical evacuations from Afghanistan during Operation Enduring Freedom, active and reserve components: U.S. armed forces, 7 October 2001–31 December 2012. *MSMR* 2013; 20(6): 2–8.
6. Cohen SP, Nguyen C, Kapoor SG, et al: Back pain during war: an analysis of factors affecting outcome. *Arch Intern Med* 2009; 169(20): 1916–23. doi: [10.1001/archinternmed.2009.380](https://doi.org/10.1001/archinternmed.2009.380).
7. Ruscio BA, Jones BH, Bullock SH, et al: A process to identify military injury prevention priorities based on injury type and limited duty days. *Am J Prev Med* 2010; 38(1): S19–33. doi: [10.1016/j.amepre.2009.10.004](https://doi.org/10.1016/j.amepre.2009.10.004).
8. Knox JB, Orchowski JR, Scher DL, Owens BD, Burks R, Belmont JJP: Occupational driving as a risk factor for low back pain in active-duty military service members. *Spine J* 2014; 14(4): 592–7. doi: [10.1016/j.spinee.2013.06.029](https://doi.org/10.1016/j.spinee.2013.06.029).
9. Simon-Armdt CM, Yuan H, Hourani LL: Aircraft type and diagnosed back disorders in U.S. navy pilots and aircrew. *Aviat Space Environ Med* 1997; 68(11): 1012–8.
10. Niebuhr DW, Krampf RL, Mayo JA, Blandford CD, Levin LI, Cowan DN: Risk factors for disability retirement among healthy adults joining the U.S. Army. *Mil Med* 2011; 176(2): 170–5. doi: [10.7205/milmed-d-10-00114](https://doi.org/10.7205/milmed-d-10-00114).
11. Sikorski C, Emerson MA, Cowan DN, Niebuhr DW: Risk factors for medical disability in U.S. enlisted marines: fiscal years 2001 to 2009. *Mil Med* 2012; 177(2): 128–34. doi: [10.7205/milmed-d-11-00250](https://doi.org/10.7205/milmed-d-11-00250).
12. Schwarzer AC, Aprill CN, Bogduck N: The sacroiliac joint in chronic low back pain. *Spine (Phila Pa 1976)* 1995; 20(1): 31–7.
13. Sembrano JN, Polly DW: How often is low back pain not coming from the back? *Spine (Phila Pa 1976)* 2009; 34(1): E27–32. doi: [10.1097/BRS.0b013e31818b8882](https://doi.org/10.1097/BRS.0b013e31818b8882).
14. Forst SL, Wheeler MT, Fortin JD, Vilensky JA: The sacroiliac joint: anatomy, physiology and clinical significance. *Pain Physician* 2006; 9(1): 61–7.
15. Vleeming A, Schuenke MD, Masi AT, Carreiro JE, Danneels L, Willard FH: The sacroiliac joint: an overview of its anatomy, function and potential clinical implications. *J Anat* 2012; 221(6): 537–67. doi: [10.1111/j.1469-7580.2012.01564](https://doi.org/10.1111/j.1469-7580.2012.01564).
16. Rashbaum RF, Ohnmeiss DD, Lindley EM, Kitchel SH, Patel VV: Sacroiliac joint pain and its treatment. *Clin Spine Surg* 2016; 29(2): 42–8. doi: [10.1097/BSD.0000000000000359](https://doi.org/10.1097/BSD.0000000000000359).
17. Dengler JD, Kools D, Pflugmacher R et al: 1-year results of a randomized controlled trial of conservative management vs. minimally invasive surgical treatment for sacroiliac joint pain. *Pain Physician* 2017; 20(6): 537–50.
18. Salman OH, Gad GS, Mohamed AA, Rafae HH, Abdelfatah AM: Randomized, controlled blind study comparing sacroiliac intra-articular steroid injection to radiofrequency denervation for sacroiliac joint pain. *Egypt J Anaesth* 2016; 32(2): 219–25. doi: [10.1016/j.egja.2015.07.005](https://doi.org/10.1016/j.egja.2015.07.005).
19. Singla V, Batra YK, Bharti N, Goni VG, Marwaha N: Steroid vs. platelet-rich plasma in ultrasound-guided sacroiliac joint injection for chronic low back pain. *Pain Pract* 2017; 17(6): 782–91. doi: [10.1111/papr.12526](https://doi.org/10.1111/papr.12526).
20. Shmigel A, Ngo L, Ensrud K, Foley R: Prescription medication use among community-based U.S. adults with chronic low back pain: a cross-sectional population based study. *J Pain* 2018; 19(10): 1104–12. doi: [10.1016/j.jpain.2018.04.004](https://doi.org/10.1016/j.jpain.2018.04.004).
21. Deyo RA, Von Korff M, Duhkoop D: Opioids for low back pain. *BMJ* 2015; 350: g6380. doi: [10.1136/bmj.g6380](https://doi.org/10.1136/bmj.g6380).
22. Servies T, Hu Z, Eick-Cost A, Otto JL: Substance use disorders in the U.S. armed forces, 2000–2011. *MSMR* 2012; 19(11): 11–6.
23. Ko G, Mindra S, Lawson G, Whitmore S, Arseneau L: Case series of ultrasound-guided platelet-rich plasma injections for sacroiliac joint dysfunction. *J Back Musculoskelet Rehabil* 2017; 30(2): 363–70. doi: [10.3233/BMR-160734](https://doi.org/10.3233/BMR-160734).
24. Marx RE: Platelet-rich plasma: evidence to support its use. *J Oral Maxillofac Surg* 2004; 62: 489–96.
25. Meheux CJ, Mcculloch PC, Lintner DM, Varner KE, Harris JD: Efficacy of intraarticular platelet-rich plasma injections in knee osteoarthritis: a systematic review. *Arthroscopy* 2016; 32(3): 495–505. doi: [10.1016/j.arthro.2015.08.005](https://doi.org/10.1016/j.arthro.2015.08.005).
26. Azadeh K, Ebrahim E, Abolghasem E, Batool H, Abbas P, Mohammad M: Platelet-rich plasma application in chondrogenesis. *Adv Biomed Res* 2014; 3: 138. doi: [10.4103/2277-9175.135156](https://doi.org/10.4103/2277-9175.135156).
27. Sakata R, Reddi AH: Platelet-rich plasma modulates actions on articular cartilage lubrication and regeneration. *Tissue Eng Part B Rev* 2016; 22(5): 408–19. doi: [10.1089/ten.TEB.2015.0534](https://doi.org/10.1089/ten.TEB.2015.0534).
28. Lee M, Silverman SM, Hansen H, Patel VB, Manchikanti L: A comprehensive review of opioid-induced hyperalgesia. *Pain Physician* 2011; 14(2): 145–61.

29. Berna C, Kulich RJ, Rathmell JP: Tapering long-term opioid therapy in chronic noncancer pain: evidence and recommendations for everyday practice. *Mayo Clin Proc* 2015; 90(6): 828–42. doi: [10.1016/j.mayocp.2015.04.003](https://doi.org/10.1016/j.mayocp.2015.04.003).
 30. Dines JS, Williams PN, ElAttrache N, et al: Platelet-rich plasma can be used to successfully treat elbow ulnar collateral ligament insufficiency in high-level throwers. *Am J Orthop (Belle Mead NJ)* 2016; 45(5): 296–300.
 31. A Hamid MS, Mohamed Ali MR, Yusof A, George J, Lee LP: Platelet-rich plasma injections for the treatment of hamstring injuries: a randomized controlled trial. *Am J Sports Med* 2014; 42(10): 2410–8. doi: [10.1177/0363546514541540](https://doi.org/10.1177/0363546514541540).
-