

# New regimen for eccentric calf-muscle training in patients with chronic insertional Achilles tendinopathy: results of a pilot study

P Jonsson,<sup>1</sup> H Alfredson,<sup>1</sup> K Sunding,<sup>2</sup> M Fahlström,<sup>3</sup> J Cook<sup>4</sup>

<sup>1</sup> Department of Surgical and Perioperative Sciences, Sports Medicine, Umeå University, Umeå, Sweden; <sup>2</sup> Capio Arthro Clinic, Stockholm, Sweden; <sup>3</sup> Department of Community Medicine and Rehabilitation, Rehabilitation Medicine, Umeå University, Umeå, Sweden; <sup>4</sup> Musculoskeletal Health School of Exercise and Nutrition Sciences, Deakin University, Burwood, Victoria, Australia

Correspondence to:  
Per Jonsson, RPT, Department of Surgical and Perioperative Sciences, Sports Medicine, Umeå University, S-901 87 Umeå, Sweden;  
per.jonsson@idrott.umu.se

Accepted 29 November 2007  
Published Online First  
9 January 2008

## ABSTRACT

**Background:** Chronic painful insertional Achilles tendinopathy is seen in both physically active and non-active individuals. Painful eccentric training, where the patients load the Achilles tendon into full dorsiflexion, has shown good results in patients with mid-portion Achilles tendinosis. However, only 32% of patients with insertional Achilles tendinopathy had good clinical results with that type of eccentric training regimen.

**Aim:** To investigate whether a new model of painful eccentric training had an effect on chronic painful insertional Achilles tendinopathy.

**Patients and methods:** 27 patients (12 men, 15 women, mean age 53 years) with a total of 34 painful Achilles tendons with a long duration of pain (mean 26 months), diagnosed as insertional Achilles tendinopathy, were included. The patients performed a new model of painful eccentric training regimen without loading into dorsiflexion. This was done as 3×15 reps, twice a day, 7 days/week, for 12 weeks. Pain during Achilles-tendon-loading activity (VAS) and patient's satisfaction (back to previous activity) were evaluated.

**Results:** At follow-up (mean 4 months) 18 patients (67%, 23/34 tendons) were satisfied and back to their previous tendon-loading activity. Their mean VAS had decreased from 69.9 (SD 18.9) to 21 (SD 20.6) ( $p<0.001$ ). Nine patients (11 tendons) were not satisfied with the treatment, although their VAS was significantly reduced from 77.5 (8.6) to 58.1 (14.8) ( $p<0.01$ ).

**Conclusion:** In this short-term pilot study this new model of painful eccentric calf-muscle training showed promising clinical results in 67% of the patients.

Insertional Achilles tendinopathy is a troublesome condition, most often seen among middle-aged to older individuals who are not physically active and are overweight.<sup>1</sup> The suggested aetiology is degenerative lesions at the enthesis due to either excessive tensile loading<sup>2,3</sup> or, more recently, to stress-shielding.<sup>4</sup> There is often a combination of pathologies, including superficial and retrocalcaneal bursitis, Haglund deformity of the upper calcaneus and tendinopathy.<sup>5,6</sup>

The mechanisms behind this painful condition are unknown<sup>7,8</sup> and treatment is often ineffective.<sup>7,9</sup> Consequently, many different conservative treatments have been proposed, including rest, nonsteroidal anti-inflammatory drugs (NSAIDs), ice, strength training and high-energy extracorporeal shock-wave therapy.<sup>1,10,11</sup>

Eccentric training is a frequently-used treatment model.<sup>12-15</sup> The eccentric exercise programme that has been shown to be successful for patients with

mid-portion Achilles tendinosis was less successful for patients with insertional Achilles tendinopathy.<sup>12</sup> It was thought that this was because of differences in pathology; however, the pathology appears similar in both mid-tendon and insertional tendinopathy.<sup>16</sup> The concept of an "enthesis organ",<sup>17</sup> where the insertion is subject to compressive forces in dorsiflexion because of impingement between tendon, bursa and bone suggests that the Achilles tendon insertion may respond to eccentric load without dorsiflexion.

This pilot study aimed to evaluate eccentric calf-muscle training without dorsiflexion in patients with chronic painful insertional Achilles tendinopathy.

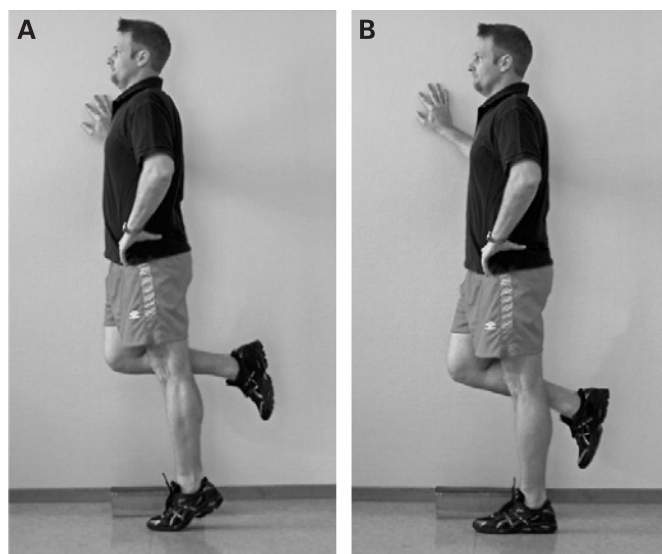
## MATERIAL AND METHODS

### Participants

Participants with pain in the Achilles tendon insertion for more than 3 months were recruited from the Sports Medicine Unit in Umeå and the Capio Arthro Clinic in Stockholm, Sweden. Participants were included if they had insertional pain and pathology based on a clinical examination (HA) and abnormality on ultrasonography. A high-resolution grey-scale ultrasound with the aid of colour Doppler (Siemens Acuson Segovia) and a linear multifrequency (8–13 MHz) probe was used. Abnormalities included Achilles tendon and bursal thickening, bone pathology (calcification, spur, fragment), and neovascularisation. The contralateral tendon was also examined. Participants with chronic inflammatory disease were excluded. All patients gave written consent to participate in the study. The study was approved by the ethics committee of the Medical Faculty at the University of Umeå.

### Eccentric training regimen

All patients were given a practical demonstration and hand-written instructions of the exercises by the same physiotherapist (PJ) at the beginning of the study. The eccentric calf-muscle training was performed in an upright body position with a straight leg. The patients performed a heel raise with the non-injured leg, then all body weight was transferred to the injured side and from the heel-raised position the patients slowly lowered the heel to the floor level (fig 1a, b). There was no load with the ankle in dorsiflexion. This was done 3 times for 15 repetitions, twice a day, 7 days/week for 12 weeks. Participants with bilateral symptoms performed a leg press while standing on a box to get up to the start position. This was done to



**Figure 1** A. Start position for the eccentric insertional Achilles exercise. The patients stand with a straight leg, all weight on the affected side. From this position the heel is slowly lowered to floor level. To get up to the start position, the patients performed a heel-raise on the unaffected side. B. End position for the eccentric insertional Achilles exercise.

avoid, as much as possible, concentric contraction in the calf muscle (fig 2).

If there was no pain during the exercise the load was increased by using a backpack that was gradually filled with weights to reach a new level of painful training (fig 3). Patients were informed that calf muscle soreness, and increased pain in the Achilles insertion, could appear during the first 2 weeks of eccentric training. All patients were contacted by telephone after 2 and 6 weeks to check training compliance. All patients could contact an investigator (PJ) during working hours if they had questions about the training programme. After 6 weeks the patients were told to slowly return to their previous sports/recreational activity.

### Evaluation

At baseline and follow-up pain was evaluated with a 100 mm visual analogue scale (VAS) that recorded the worst amount of pain during Achilles-tendon-loading activity.<sup>18</sup> After 12 weeks, the participants recorded whether they were “satisfied” (back to previous tendon loading activity) or “not satisfied” (not back to previous tendon loading activity) with treatment.

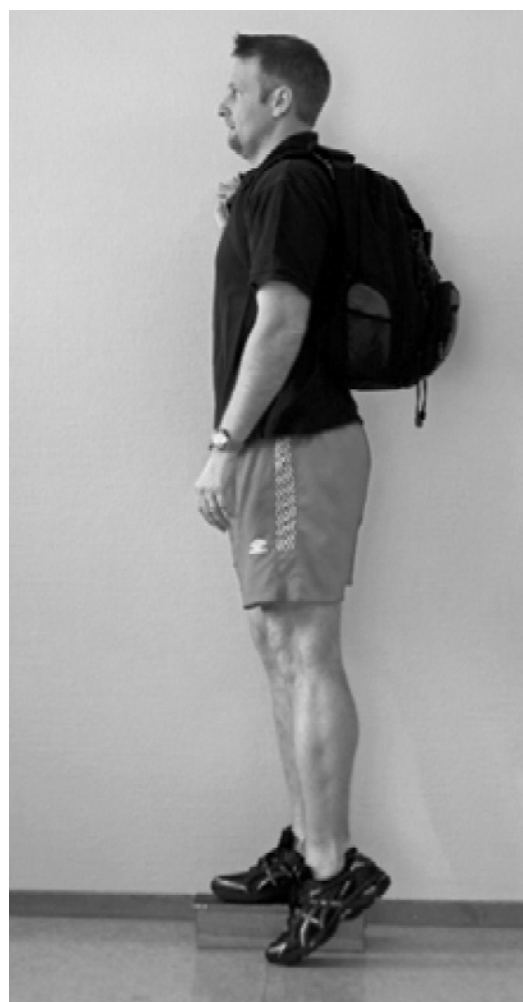### Statistical analysis

Data were entered into statistics software (SPSS version 11.5, SPSS Inc., Chicago, Illinois, USA). The results are presented as mean (SD). Differences between the groups were calculated using a Student t test for independent samples. A p value <0.05 was considered significant.

### RESULTS

Twenty-seven participants (12 men, 15 women, mean age 53.4 years, range 25–77) with chronic pain in the Achilles insertion were included in the study (table 1).

Twenty of the participants had unilateral symptoms, seven had bilateral symptoms, giving a total of 34 painful Achilles tendons. All participants had a long duration of pain (mean



**Figure 2** If there were bilateral symptoms the patients performed a leg press while standing on a box or a staircase to get up to the start position. This was done to avoid as much as possible concentric because of contraction in the calf muscle.

26.5 months, range 6–96) and were not able to participate in their regular Achilles-tendon-loading activities because of pain.

Participants undertook a variety of activities, including walking (15), running (6) and other sports (6) and had tried a variety of treatments including rest (27), NSAID (22), local cortisone injections (6), eccentric training (13), shock-wave therapy (1), laser (1), ultrasound (8), heel-lift (8) and acupuncture (5).

At baseline the mean estimated pain on the VAS was 72.4 (SD 16.5) for the whole group. At the follow-up (mean 4 months), 18 patients (with 23 painful tendons) were satisfied

**Table 1** Baseline characteristics of 27 subjects (34 tendons) with chronic insertional Achilles tendinopathy

Age (years)	53.4 (13.0) (25–77)
Weight (kg)	85.5 (18.0) (52–150)
Height (cm)	172.7 (8.9) (154–187)
BMI (kg/m <sup>2</sup> )	28.7 (6.3) (19.8–53.1)
Duration of symptoms (months)	26.5 (21.1) (6–96)
VAS at baseline	72.4 (16.5) (21–96)

Results expressed as mean (SD) (range).



**Figure 3** If there was no pain during the exercise the patients gradually filled a backpack with weights to reach a new level of painful training.

with the treatment and were back to their previous Achilles-tendon-loading activities. In this group, estimated pain on the VAS had decreased significantly from 69.9 (18.9) to 21.0 (20.6) ( $p < 0.001$ ).

Nine patients (with 11 painful tendons) were not satisfied, though the estimated pain on the VAS had decreased significantly from 77.5 (8.6) to 58.1 (14.8) ( $p < 0.006$ ). These nine patients were not back in their previous Achilles-tendon-loading activities.

During the 12-week training regimen one patient could not perform the exercise because of pain.

This patient was registered as unsatisfied with the treatment.

Age, gender, body mass index (BMI), duration of symptoms, activity level, occurrence of bone pathology unilateral or bilateral tendon pathology had no effect on the outcome of the treatment (table 2).

## DISCUSSION

The patients in our study had had a long duration of insertional pain, and the majority had pathology in multiple tissues (tendon, bone, bursa). Therefore, we believe that our group of patients is representative for individuals with insertional Achilles tendinopathy.

Painful eccentric training beyond plantargrade has shown good clinical results in patients with mid-portion Achilles tendinosis.<sup>12</sup> To the best of our knowledge only one study has evaluated this type of painful eccentric training on patients

**Table 2** Characteristics of 34 tendons in 27 subjects with chronic insertional Achilles tendinopathy: comparison between subjects who were satisfied and not satisfied with treatment

Variable	Satisfied (n = 23)	Not satisfied (n = 11)	p Value
Female	15/23	3/11	
Age	54.9 (14.7)	50.3 (7.8)	0.336
Height (cm)	171.1 (9.3)	176.1 (7.1)	0.130
Weight (kg)	86.7 (19.8)	83.0 (14.0)	0.584
BMI	29.7 (7.0)	26.7 (3.9)	0.206
Duration of symptoms (months)	23.3 (22.6)	33.4 (16.3)	0.196
Haglund's deformity	18/23	9/11	0.813
Bursitis	17/23	5/11	0.110
Bone spurs	20/23	5/11	0.373
Baseline VAS	69.9 (18.9)	77.5 (8.6)	0.115
Follow-up VAS	21.0 (20.6)	58.1 (14.8)	<0.001*

Results expressed as mean, standard deviation and p value.

\*Significant p value <0.05.

with chronic pain in the Achilles insertion. In that study only 32% of the patients had good clinical results.<sup>12</sup> It was hypothesised that the reason for the poor results was a mechanical impingement between the prominent calcaneus and the tendon and bursa, when the ankle was in the dorsiflexed position.

In the current study, based on the findings from the previous study,<sup>12</sup> we used an eccentric training model without dorsiflexion in the ankle joint to avoid possible mechanical impingement. The new training model resulted in 67% satisfied patients. The results were similar whether there was tendon pathology alone, Haglund's deformity, bursae pathology or bone spurs. Interestingly, combined pathology in the insertion does not seem to exclude a satisfactory response to this eccentric training regimen. This might be of clinical importance, since surgical treatment of this condition has shown varying clinical results.<sup>19–22</sup>

Interestingly, in a recent study ultrasound and Doppler-guided sclerosing polidocanol injections, targeting the area with increased vascularity in the Achilles tendon insertion, were shown to give good clinical results in patients with chronic

## What is already known on this topic

- ▶ Chronic painful insertional Achilles tendinopathy is seen in both physically active and non-active individuals.
- ▶ The mechanisms behind this painful condition are unknown and treatment is often ineffective.
- ▶ Painful eccentric calf-muscle training has shown good results in patients with mid-portion Achilles tendinopathy, while the results in insertional Achilles tendinopathy have been poor.

## What this study adds

- ▶ This pilot study showed promising clinical results with a new regimen for painful eccentric calf-muscle training in patients with chronic painful insertional Achilles tendinopathy.
- ▶ The patients performed painful eccentric training without loading in dorsiflexion to avoid impingement between tendon, bursa and bone.

insertional pain.<sup>23</sup> This possibly indicates that the increased vascularity, together with nerves, is closely related to the source of pain. In that study, the increased vascularity was found in relation to the tendon, bursae, and bone, alone, or in combination. In the current study there are similar findings. We have not fully evaluated the tendon changes before and after this type of training, but it seems that the increased blood flow found at inclusion decreased dramatically in the successfully treated patients, after the 12 weeks of eccentric training. Evaluation of the tendon structure and blood flow, before and after treatment, is in focus for a future study.

In conclusion, 12 weeks of painful eccentric calf-muscle training without dorsiflexion showed promising clinical results in 67% of the patients. Longer-term follow-ups with more participants are needed to verify the results.

**Competing interests:** None.

**Ethics approval:** Ethics approval was obtained from the Medical Faculty, University of Umeå.

**Patient consent:** Obtained.

## REFERENCES

1. **Meyerson MS**, Mcgarvey W. Disorders of the Achilles tendon insertion and Achilles tendinitis. *Instr Course Lect* 1999;**48**:211–8.
2. **Benjamin M**, Evans EJ, Copp L. The histology of tendon attachments to bone in man. *J Anat* 1986;**149**:89–100.
3. **Rufai A**, Ralphs JR, Benjamin M. Structure and histopathology at the insertional region of the human Achilles tendon. *J Orthop Res* 1995;**13**:585–93.
4. **Maganaris CN**, Narici MV, Almekinders LC, et al. Biomechanics and pathophysiology of overuse tendon injuries. Ideas on insertional tendinopathy. *Sports Med* 2004;**34**:1005–17.
5. **Vega MR**, Cavolo DJ, Green RM, et al. Haglund's deformity. *J Am Podiatr Med Assoc* 1984;**74**:129–35.
6. **Kvist M**. Achilles tendon injuries in athletes. *Ann Chir Gynaecol* 1991;**80**:188–201.
7. **Hunter G**. The Conservative management of Achilles tendinopathy. *Physical Therapy in Sport* 2000;**1**:6–14.
8. **Khan KM**, Cook JL, Maffulli N, et al. Where is the pain coming from in tendinopathy? It may be biochemical, not only structural, in origin. *Br J Sports Med* 2000;**34**:81–3.
9. **Cook JL**, Kahn KM, Purdam C. Achilles tendinopathy. *Man Ther* 2002;**7**:121–30.
10. **Weiler JM**. Medical modifiers of sports injury. The use of nonsteroidal anti-inflammatory drugs (NSAIDs) in sports soft-tissue injury. *Clin Sports Med* 1992;**11**:625–44.
11. **Furia JP**. High-energy extracorporeal shock wave therapy as a treatment for insertional Achilles tendinopathy. *Am J Sports Med* 2006;**34**:733–40.
12. **Fahlström M**, Jonsson P, Lorentzon R, et al. Chronic Achilles tendon pain treated with eccentric calf-muscle training. *Knee Surg Sports Traumatol Arthrosc* 2003;**11**:327–33.
13. **Woodley BL**, Newsham-West RJ, Baxter GD. Chronic tendinopathy: effectiveness of eccentric exercise. *Br J Sports Med* 2007;**41**:188–98.
14. **Kingma JJ**, de Knikker R, Wittink HM, et al. Eccentric overload training in patients with chronic Achilles tendinopathy: a systematic review. *Br J Sports Med* 2007;**41**:e3.
15. **Mafi N**, Lorentzon R, Alfredson H. Superior short-term results with eccentric calf-muscle training compared to concentric training in a randomized prospective multicenter study on patients with chronic Achilles tendinosis. *Knee Surg Sports Traumatol Arthrosc* 2001;**9**:42–7.
16. **Maffulli N**, Testa V, Capasso G, et al. Similar histopathological picture in males with Achilles and patellar tendinopathy. *Medicine and Science in Sport and Exercise* 2004;**36**:1470–5.
17. **Benjamin M**, Moriggl B, Brenner E, et al. The "entheses organ" concept: why enthesopathies may not present as focal insertional disorders. *Arthritis Rheum* 2004;**50**:3306–13.
18. **Melzack R**, Katz J. Pain measurement in persons in pain. In: Wall PD, Melzack R, editors. *Textbook of pain*. London: Churchill Livingstone, 1999:409–26.
19. **Nesse E**, Finsen V. Poor results after resection for Haglund's heel. Analysis of 35 heels in 23 patients after 3 years. *Acta Orthop Scand* 1994;**65**:107–9.
20. **Maffulli N**, Binfield P, Moore D, et al. Surgical decompression of chronic central core lesions of the Achilles tendon. *Am J Sports Med* 1999;**27**:747–52.
21. **Paavola M**, Orava S, Leppilahti J, et al. Chronic Achilles tendon overuse injury: Complications after surgical treatment. An analysis of 432 consecutive patients. *Am J Sports Med* 2000;**28**:77–82.
22. **Boberg JS**, Anania MC. Retrocalcaneal exostosis: Anatomy and a new surgical approach. *J Am Podiatr Med Assoc* 2002;**92**:537–43.
23. **Öhberg L**, Alfredson H. Sclerosing therapy in chronic Achilles tendon insertional pain: results of a pilot study. *Knee Surg Sports Traumatol Arthrosc* 2003;**11**:339–43.

### Need a helping hand with your career choices?

If you need to take stock, get some career advice or find out about the choices available to you then the **BMJ Careers Fair** is the place to do it. You can find out about how best to present yourself to potential employers, polishing up your CV, working abroad, locum working and much more.

#### BMJ Careers Fairs – dates for your diary

3–4 October 2008 – Business Design Centre, London

10–11 October 2008 – Thinktank, The Science Museum, Birmingham – working in partnership with the West Midlands Deanery

Register now at [bmjcareersfair.com](http://bmjcareersfair.com)

**BMJ Careers**